



ISSN: 2476-8642 (Print)

ISSN: 2536-6149 (Online)

www.annalsofhealthresearch.com
Indexed in: African Index Medicus,
Index Copernicus & Google Scholar
Member of C.O.P.E and D O.A.J

Annals of Health Research

IN THIS ISSUE



- Health and National Development
- Booked Nullipara and Primipara
- Smartphone Addiction
- Blood Transfusion in Children
- *Telfairia occidentalis* on Blood And Liver Parameters
- Lateral Invertogram
- Bacterial Colonization of Automated Teller Machines
- Subcutaneous Mastectomy
- Effects of Extracts of *Musanga cercropoides*
- *Nigella sativa* and Essential Tremor
- *Allium sativum* and Male Fertility
- Complications of Mastectomy
- *Nigella sativa* and ADHD Treatment

**PUBLISHED BY THE MEDICAL
AND DENTAL CONSULTANTS ASSOCIATION
OF NIGERIA, OOUTH, SAGAMU, NIGERIA.**

ORIGINAL RESEARCH

Surgical management of gynaecomastia: Experience from a tertiary health facility in Southwest Nigeria

Salami BA *¹, Ayoade BA¹, Adekoya AO¹, Odusan O², Fatungase OM³

¹Department of Surgery, ²Department of Medicine, ³Department of Anaesthesia, Olabisi Onabanjo University, Sagamu

*Correspondence: Dr. BA Salami, Department of Surgery, Olabisi Onabanjo University, Sagamu. Email: salami.babatunde@oouagoiwoye.edu.ng, tsalamis@yahoo.com;
ORCID - <https://orcid.org/0000-0003-4940-8958>.

Abstract

Background: Gynaecomastia is the benign enlargement of the male breast as a result of glandular proliferation, usually resulting in feminine appearance. The treatment is usually surgical for cosmetic reasons.

Objective: To describe the local experience with the surgical treatment of gynaecomastia by conventional subcutaneous mastectomy.

Methods: This is a retrospective study of all cases of gynaecomastia seen at the surgical out-patient department of the Olabisi Onabanjo University Teaching Hospital, Sagamu, covering the period from January 2009 to October 2019. The data obtained included age, duration of symptoms, treatment, postoperative complications and type of anaesthesia.

Results: A total of twenty-three cases were seen. The mean age was 26.4±17.5 years with an age range of 15 to 84 years. The mean duration of symptoms was 2.9±3.6 years. About 70% of the cases were aged less than 21 years. Twenty-one patients (91.3%) had a subcutaneous mastectomy, and local anaesthesia was deployed for the procedure in 16 (76.2%) cases. Two patients (9.5%) developed postoperative haematoma while one patient developed severe keloid at the surgical site.

Conclusion: Subcutaneous mastectomy for gynaecomastia can be safely done under local anaesthesia and it gives a good cosmetic effect with minimal postoperative complications.

Keywords: Breast, Gynaecomastia, Local Anaesthesia, Subcutaneous mastectomy.

Introduction

Gynaecomastia is the benign generalised enlargement of the male breast, which is mainly prevalent at puberty. [1-3] Most cases are idiopathic [3] but may also be a result of various diseases, including hepatitis, renal and endocrine problems. [4] Medications have been reported to cause about 25% of cases of new-onset in adults. [5,6] It is usually bilateral and one of the commonest breast diseases among males. [2,7] A trimodal age distribution of

gynaecomastia is known: this includes the neonatal period, pubertal period and in the elderly. [7,8] Gynaecomastia has an overall prevalence of 32-65%. [2] The prevalence is about 60-90% among neonates, 50-60% in peri-pubertal age and up to 70% in the 50-60 years age group. [1,7]

True gynaecomastia occurs as a result of hypertrophy of glandular and stromal tissues while pseudo gynaecomastia occurs from the accumulation of areolar fat, with no real

proliferation of glandular tissue. [1,7,9] The latter tends to be common among obese men. [6] The usual presentation is breast swelling which lasts 6-12 months in the pubertal period. This regresses in 95% of cases. [10] When investigative workup does not reveal any underlying disease, reassurance and periodic follow up is recommended before surgical treatment is offered. In some patients, pain and tenderness may require medications. The usual investigative workup includes the estimation of Body Mass Index (BMI), examination of the testes and hormonal assay for testosterone, prolactin and luteinising hormone. [6,7] Mammography was found to be fairly accurate in distinguishing benign from malignant male breast disease. [7] Extensive investigation is unlikely to be helpful if no history or physical finding is suggesting an underlying pathology. [6]

Surgery is usually considered in cases with considerable discomfort, long-standing gynaecomastia of greater than 12 months duration, poor body image, psychological stress, and suspected malignancy. [11-13] If gynaecomastia persists for more than one year, instances of regression are rare. This is due to the predominance of dense fibrous tissue in the breast. [12,13] The ultimate goal of surgery in the treatment of gynaecomastia is to restore adequate cosmetic results, with symmetry of the chest and minimise scars. The various surgical techniques include subcutaneous mastectomy with or without liposuction. Liposuction should be reserved for patients with pseudogynaecomastia. Therefore, the surgical treatment of gynaecomastia requires an individualised patient-specific approach. [14]

Subcutaneous mastectomy is usually performed by direct resection of the glandular tissue through a circumareolar or periareolar incision. [15] Postoperative complications may include haematoma, seroma, numbness, necrosis, hypertrophic scar, nipple retraction, cosmetic non-satisfaction, and breast asymmetry. [16, 17]

The present study was carried out to describe the local experience with subcutaneous mastectomy in the treatment of gynaecomastia, especially with the use of local anaesthesia. The literature search did not reveal many similar studies in this environment.

Methods

The study was a retrospective analysis of all the cases of gynaecomastia seen at the Surgical Out-patient Department of the Olabisi Onabanjo University Teaching Hospital, Sagamu, southwest Nigeria over the period from January 2009 to October 2019. The hospital records of all the cases of gynaecomastia were retrieved and the data extracted included the age, duration of symptoms, laterality (Unilateral or Bilateral), treatment, type of operation (at one or two sittings), type of anaesthesia and postoperative complications. Data analysis was carried out using IBM SPSS version 21.

Operative procedure

Subcutaneous mastectomy was carried out with either local anaesthesia or general anaesthesia. Local Anaesthesia was achieved by field block using 1% Lidocaine with adrenaline not exceeding the maximum safe dose of 4.5mg/kg (not to exceed 300mg). Alternatively, general anaesthesia was achieved with endotracheal intubation. Mastectomy was carried out using a periareolar incision.

Results

Twenty-three cases of gynaecomastia were managed during the period of the retrospective study. The mean age was 26.3±17.5 years, with an age range of 15 to 84years. (Figure 1)

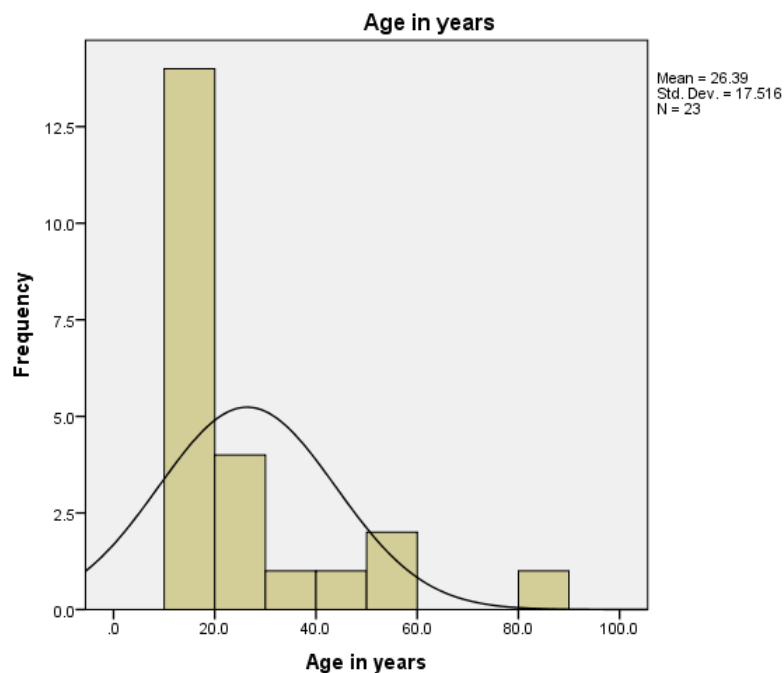


Figure 1: Age distribution of the 23 Cases of Gynaecomastia

Twenty-one (91.3%) had subcutaneous mastectomy while 2(8.7%) resolved spontaneously. Out of the 23 cases, 20(87%) were bilateral and 3(13%) were unilateral. The mean age of the unilateral cases was 66.3±15.4 years while the mean age of the bilateral cases was 20.4±6.4 years with an age range of 15 to 40 years. Seventy percent of all the cases of gynaecomastia were below the age of 21years.

The mean duration of symptoms was 2.9±3.6 years with a range of 0.5 to 15 years. Sixteen (76.2%) cases had subcutaneous mastectomy under local anaesthesia while 5(23.8%) had general anaesthesia. Seventeen (81%) of the 21 cases had the surgery in one sitting while 4(19%) had the procedure in two sittings. The mean interval between the sittings was 8.8days with a range of 2 to 21 days.

Out of the 21 mastectomy cases, the complications recorded included gangrenous skin patch (2; 9.5%), haematoma (2; 9.5%) collection and keloid (1; 4.8%). The keloid was severe and required intralesional

Triamcinolone injection on follow-up care. There was no incidence of wound infection. Figures 2 and 3 depict pre-operative and post-operative pictures of cases of gynaecomastia.

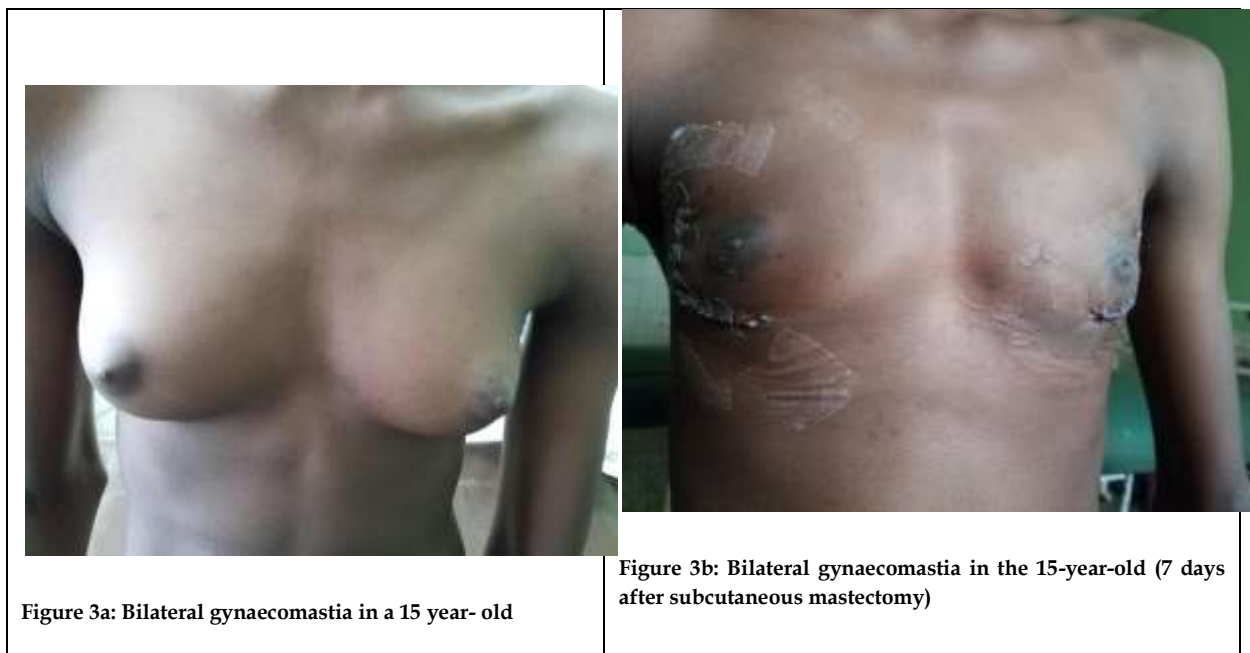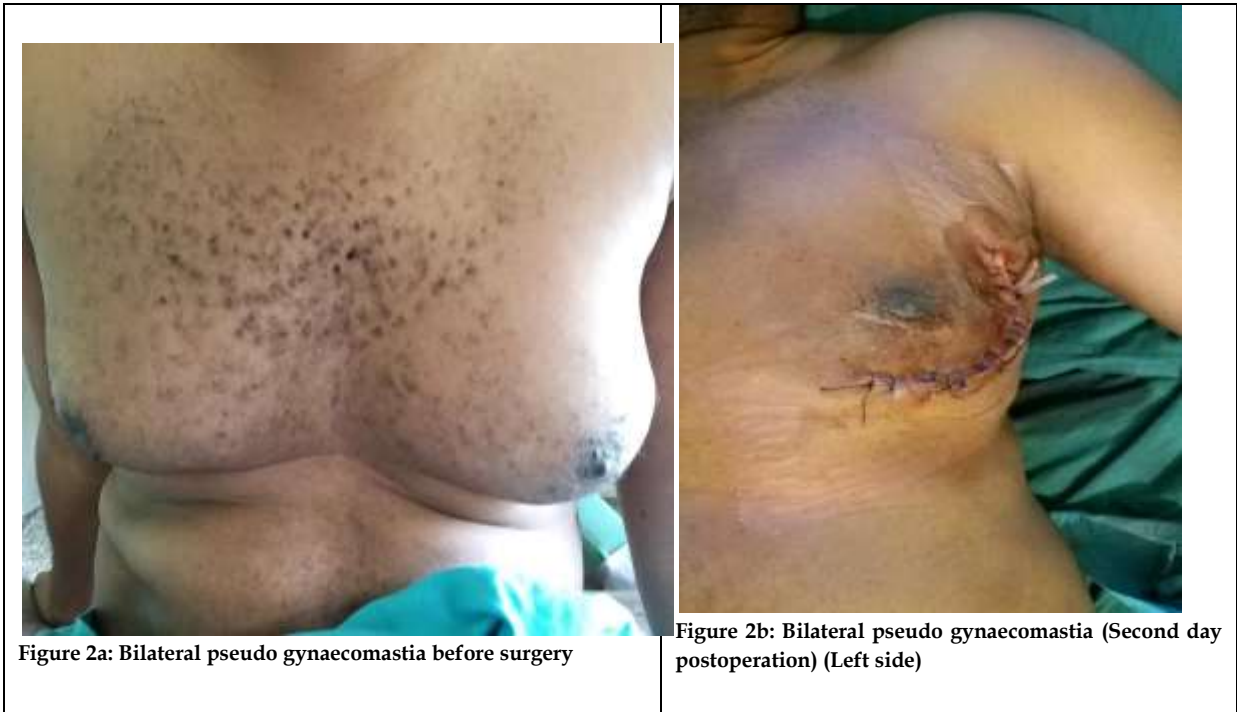Discussion

Gynaecomastia is a benign condition and most times does not present with pain or discomfort. It is, sometimes, a sign of underlying pathology. Surgery is the gold standard therapy for gynaecomastia, especially when it becomes symptomatic with pain, tenderness or psychological stress. [9]

The mean age of the cases of gynaecomastia in the present study was 26.3years, with a range of 15 to 84 years. This is similar to the finding in a study by Lanitis *et al* in which the mean age of patients who had surgery for gynaecomastia was 26 years with a range of 11 to 82 years. [18] The mean age in the study by Muneer *et al* was 30.5 years. [3] This higher value can be attributed to the distribution of

the subjects as they were adults in that study and most of the cases belonged to the age

group 21 to 30 years.



Studies have shown that the age distribution for gynaecomastia is trimodal with peaks in the neonatal period, pubertal age and the elderly. [2,7,8] In the present study, 70% of the cases were below the age of 21 years. This is probably because the study was limited to patients who had a subcutaneous mastectomy and not a general review of gynaecomastia cases. Breast enlargement usually regresses with pubertal progression and only a few have persistent gynaecomastia. [2,7,13]

Gynaecomastia is usually bilateral in about half of the cases. [9,10] In the present study, a greater percentage (87%) had bilateral gynaecomastia while 13% had unilateral gynaecomastia. The study by Longheu *et al* showed a fairly similar result, in which 76% were bilateral and 24% were unilateral. [19] This higher percentage of bilateral gynaecomastia in the present study is probably because most of the patients were adolescent males. Pubertal gynaecomastia is usually physiologic and bilateral and the patients usually present when there is no spontaneous regression.

In the present study, 76.2% had surgery under local anaesthesia while 23.8% had general anaesthesia. This is at variance with the study by Longheu *et al* in which a greater percentage (78%) had surgery under general anaesthesia. [19] The reason for this difference is probably the high cost of general anaesthesia to the patients compared to local anaesthesia at the location of the present study. In the study by Lee *et al*, all the patients had general anaesthesia. [20] This was probably because the patients had subcutaneous mastectomy combined with liposuction.

Eighty-one percent of the cases in the present study had surgery at one sitting, while 19% had their surgery at two sittings. The reasons for having the surgery at two sittings in this study included an unexpected long duration of surgery and low pain threshold. Though this may not be the best practice, there were no

complications. However, there was no study documenting bilateral subcutaneous mastectomy at two sittings on an extensive literature search. The postoperative complications noted in the present study included haematoma, necrotic skin patch and severe keloid in a patient who eventually required intralesional Triamcinolone (Kenalog®) injection. There was no incidence of wound infection. Other studies have shown a similar spread of postoperative complications of haematoma and hypertrophic scar formation. [16,19] Nipple retraction and recurrence of gynaecomastia had also been reported. [16] Other studies reported acute major complications such as severe haematoma requiring intervention and wound infection, [3,18] which was not our experience in this study. The present study was limited by the small sample size and the retrospective design which restricted the parameters available for analysis.

Conclusion

Subcutaneous mastectomy for gynaecomastia performed under local anaesthesia is a safe procedure. In bilateral cases of gynaecomastia, the surgery can be done at two sittings when indicated. The complications of the procedure were minimal and gave a good cosmetic effect.

Authors' Contributions: SBA conceived the study. SBA, OO, and FOM did the literature review. SBA, ABA, and AAO did data collection and analysis. All the authors participated in drafting and reviewing the final draft of the manuscript. All the authors approved the final version of the manuscript.

Conflict of Interest: None


Funding: Self-funded.

Publication History: Submitted 21 November 2019; Accepted 28 February 2020.

References

1. Hassan RM. Modified Benelli procedure for subcutaneous mastectomy: A randomised controlled trial. *Am Med Surg* 2019; 47: 19-23. <http://doi.org/10.1016/j.amsu.2019.09.007>
2. Cuhaci N, Polat SB, Evranos B, Ersoy R, Cakir B. Gynaecomastia; Clinical evaluation and management. *Indian J Endocr Metab* 2014; 18(2): 150-158.
3. Muneer A, LaghariZH, Shoikh AR, Laghari QA. Gynaecomastia: Management in a developing country. *J AyubMed Coll Abbottabad* 2009; 21(3): 7-11
4. Walker BP, Toft AD. Endocrine disease. *Davidsons Principles and Practice of Medicine* 19th Edition. Churchill Livingstone London 2003: 706-707.
5. Rahmani S, Turton P, Shaaban A, Dali B. Overview of Gynaecomastia in the modern era and the Leeds Gynaecomastia investigation algorithm. *Breast J* 2011; 17: 246-255.
6. Baros AC, SampaioMde C. Gynaecomastia: pathophysiology, evaluation, and treatment. *Sao Paulo Med J* 2012; 130: 187-197.
7. Johnson RE, Murad MH. Gynaecomastia: Pathophysiology, Evaluation, and Management. *Mayo Clin Proc* 2009; 84(11): 1010-1015.
8. Gikas P, Mokbel J. Management of gynaecomastia. An update. *Int J Clin Pract* 2007; 61: 1209-1215.
9. Johnson RE, Kermott CA, Murad MH. Gynaecomastia - evaluation and current treatment options. *Thera Clin Risk Manage* 2011; 7: 145-148.
10. Braunstein CD. Clinical practice gynaecomastia. *N Eng J Med* 2007; 357(12): 1229-1237.
11. Bembo SA, Carlson HE. Gynaecomastia: Its features and when and how to treat it. *Cleve Clin J Med* 2004; 71: 511-517.
12. Carlson HE. Approach to the patient with gynaecomastia. *J Clin Endocrinol Metab* 2011; 96: 15-21.
13. Bhasin S. Testicular Disorders. In: Kronenberg HM, Melmed S, Polonsky KS, Larsen PR (Editors). *William textbook of Endocrinology* 11th Edition, Philadelphia Saunders Elsevier: 2008: 669-674.
14. Handschin AE, Bietry D, Husler R, Constantinescu M, Banc A. Surgical treatment of gynaecomastia. - a 10-year analysis. *World J Surg* 2008; 32(1): 38-44.
15. Choi BS, Lee SR, Byun GY, Hurang SB, Kuo BH. The characteristics and short term surgical outcome of adolescent gynaecomastia. *Aesthetic Plast Surg* 2017; 41(5): 1011-1021.
16. Fischer S, Hirsch T, Hirsche C, Kiefer J, Kueckelhaus M, Germann G, et al. Surgical treatment of primary gynaecomastia in children and adolescents. *Paediatr Surg Int* 2014; 30(6): 641-647.
17. Bailey SH, Guenther D, Constantine F, Rohrich RJ. Gynaecomastia management: an evolution and refinement in technique at UT Southwestern Medical Centre. *Plast Reconstr Surg Glob Open* 2016; 4 e734. [http://refhub.elsevier.com/S2049-0801\(1G\)30125-6/Sref11](http://refhub.elsevier.com/S2049-0801(1G)30125-6/Sref11)
18. Lanitis S, Starren E, Read J, Heymann T, Tekkis P, Hadjiminias DJ, et al. Surgical management of gynaecomastia: outcome from our experience. *Breast* 2008; 17(6): 596-603.

19. Longheu A, Medas F, Corrias F, Farris S, Tatti A, Pisano G, *et al.* Surgical management of Gynaecomastia: Experience of a general surgery centre. *G Chir* 2016; 37(4): 150-154.
20. Lee BH, Kwon YJ, Park JW, Hwang JH, Kim KS, Lee SY. Gynaecomastia surgery is associated with improved nipple location in young Korean patients. *Arch Plast Surg* 2014; 41(6): 748-752.

	This is an Open Access document licensed for distribution under the terms and conditions of the Creative Commons Attribution License (http://creativecommons.org/licenses/by-nc/4.0). This permits unrestricted, non-commercial use, reproduction and distribution in any medium provided the original source is adequately cited and credited.
---	---