



ISSN: 2476-8642 (Print)

ISSN: 2536-6149 (Online)

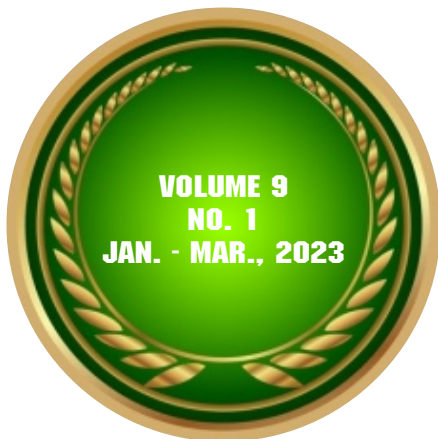www.annalsofhealthresearch.com

African Index Medicus, Crossref, African Journals
Online & Google Scholar

C.O.P.E & Directory of Open Access Journals

Annals of Health Research

IN THIS ISSUE



- Calcium and Magnesium Levels in Pre-eclampsia
- Skin-Lightening Practices in Lagos
- Behavioural Perception of Drug Abuse
- Medication Adherence Among the Elderly
- Prostate Specific Antigen Testing
- Bloodstream Infections in Stroke
- Perinatal Outcome in Nuchal Cords
- Physical Activity Among Adults
- Ectodermal Dysplasia

**PUBLISHED BY THE MEDICAL
AND DENTAL CONSULTANTS ASSOCIATION
OF NIGERIA, OOUTH, SAGAMU, NIGERIA.**

www.mdcan.outh.org.ng

CASE REPORT

Ectodermal Dysplasia with Bilateral Punctal Agenesis in a Nigerian Child: A Case Report

Owoeye JFA¹, Monsudi KF*², Yusuf IA¹, Bamidele O¹

¹Department of Ophthalmology, UIITH Ilorin, Kwara State, Nigeria

²Department of Ophthalmology, Federal Medical Centre, Birnin-Kebbi, Kebbi State, Nigeria

*Correspondence: Dr KF Monsudi, P.M.B 1126, Birnin-Kebbi, Kebbi State, Nigeria. E-mail: kfmshood@yahoo.com ; ORCID - <https://orcid.org/0000-0002-6872-2689>.

Summary

Ectodermal dysplasia (ED) is a hereditary condition that occurs worldwide. It is due to abnormality in the development of skin and its appendages (hair, teeth and nail). ED also presents with ocular manifestations. This case of ED is reported to highlight ocular manifestations such as bilateral punctal agenesis, madarosis and blepharitis. The need for a multi-disciplinary approach in managing such cases is underscored.

Keywords: Ectodermal Dysplasia, Nigeria, Punctal agenesis, Skin appendages.

Introduction

Ectodermal dysplasia (ED) is a heterogeneous group of congenital disorders, mostly inherited in an X-linked pattern, first reported by Thurnam in 1848.^[1] The term "ectodermal dysplasia" was coined by Weech in 1929.^[2] ED consists of a large, heterogeneous, congenital, non-progressive group of disorders defined by primary defects in the development of two or more tissues derived embryologically from the ectoderm. The primary tissues affected are the teeth, skin and its appendages (sebaceous glands, eccrine glands, hair follicles and nails).^[3]

Over 170 specific syndromes have been described with different modes of inheritance.^[4] ED classification system was first proposed by Freire-Maia and Pinheiro in 1982,^[5] with an additional modification in 1994 and 2001.^[6] The patients were divided into subgroups based on the presence or absence of trichondysplasia,

abnormal dentition, onchondysplasia and dyshidrosis. The most common syndromes within this group are hypohidrotic ED and hidrotic ED.^[4] The hypohidrotic and hidrotic forms have varying manifestations of hair, teeth and nail abnormalities. The hypohidrotic form (Christ-Siemens-Touraine syndrome) is the most common, with significant involvement of the sweat glands, and mostly inherited as an X-linked recessive disorder compared to the hidrotic form (Clouston syndrome), which spares the sweat glands and has an autosomal dominant mode of inheritance.^[7] Many cases with ocular manifestations of ED have been reported worldwide.^[8-12] Familusi et al. reported the first ED case in Nigeria^[13] in 1975. Following this, many cases of ED have subsequently been reported in Nigeria^[14-18], but no single case has been reported on ocular manifestations in Nigerian subjects.

Worldwide, the frequency of the different forms of ED in a given population varies greatly and ranges from 1 in 10,000 to as low as 1 in 100,000 births. [19-21] Any tissue embryologically derived from the ectoderm, be it surface ectoderm or neuroectoderm, could be affected. Some cases may even have a mesodermal component to this disorder. [22]

Therefore, this case of hidrotic ectodermal dysplasia with bilateral punctal agenesis, madarosis and blepharitis in a Nigerian child is reported. This case deserves reporting because of its unusual features and difficulty in providing optimal management.

Case Description

A 4-year-old female child was brought to the Department of Ophthalmology, University of Ilorin Teaching Hospital, Ilorin, Nigeria, by the parents with a history of bilateral tearing since birth. There were associated recurrent redness, itching of the eyelid margin and purulent discharge which subsides with the instillation of topical antibiotics (chloramphenicol ointment and ofloxacin eye drop). There was no history of reduction in vision, swelling in the medial canthi region, heat intolerance, dysphonia, hoarseness of voice or hearing defect. The mother gave a history of discolouration and irregular growth of the child's dentitions and nails as well as uneven growth and loss of scalp hair. There was no family history of similar abnormalities or consanguineous marriage.

Physical examination revealed frontal bossing with sparse, fine hair and loss of hair on the scalp along the central part of the sagittal suture (Figure 1), nail dystrophy involving all digits (Figure 2) and malformed teeth (Figure 3).

Ocular examination of both eyes revealed visual acuity of 6/9 in the Right Eye and Left Eye respectively, blepharitis, madarosis (Figure 4) and bilateral absence of the puncta in the

upper or lower lids (all four puncta) (Figure 5) with the presence of lacrimal papillae on examination under anaesthesia.

The posterior segment in both eyes was essentially normal, and intra-ocular pressure was within the normal range bilaterally. Based on the history and examination findings, ectodermal dysplasia was diagnosed. All the requested investigations (Full Blood Count, Random Blood Glucose, and urinalysis) gave results within the normal range. The parents were extensively counselled on the child's clinical condition. The child was co-managed with the dermatologist, paediatrician and dental surgeon (prosthodontist). She subsequently had bilateral conjunctivo-dacryocysto-rhinostomy (C-DCR) with the placement of a Lester Jones tube in both eyes, and blepharitis was adequately managed with topical antibiotics (chloramphenicol ointment, and gutte ofloxacin), gutte diclofenac and scrubbing of the eyelids with baby shampoo.

The researchers obtained informed consent to use the child's data for this report from the child's mother. Ethical approval for the study was also obtained from the Research Ethics Committee of the Federal Medical Centre, Birnin-Kebbi, Kebbi State, Nigeria.

Discussion

The index case is similar to the hidrotic form as there was no history of heat intolerance or recurrent fever, even though there was no family history of ED. Several ED syndromes may also manifest in association with mid-facial defects, mainly cleft lip and palate. [4] ED is often seen among whites [23] but rare among blacks. Hidrotic ED has been reported in several members of a French-Canadian family. [3] Clinical recognition of ED varies from birth to childhood, depending on the severity of symptoms and the recognition of associated complications, as many patients are not diagnosed until infancy or childhood when

dental, nail, and hair abnormalities have started manifesting. [3]

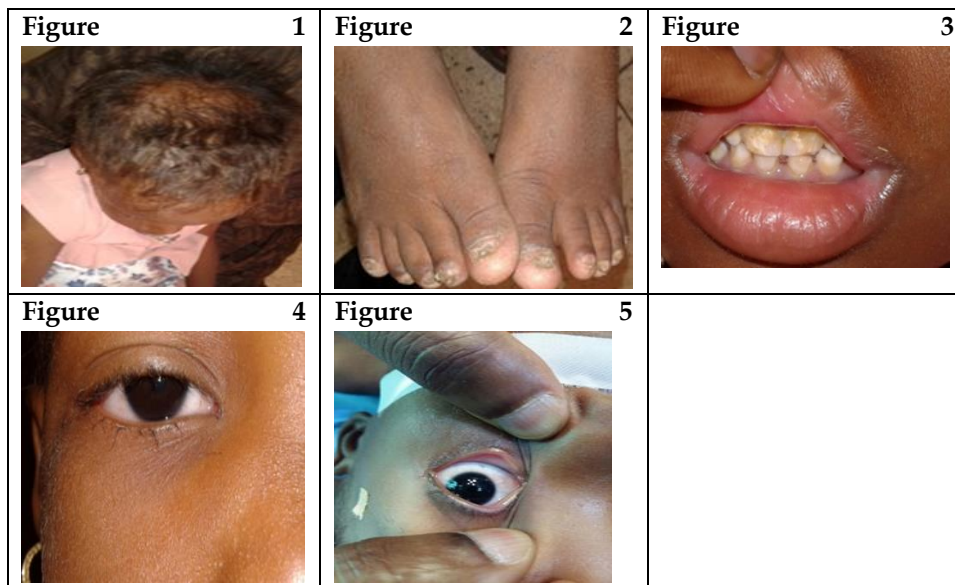


Figure 1: Sparse, fine hair with hair loss
Figure 2: Toes of both feet showing nail dystrophy
Figure 3: Malformed teeth
Figure 4: Madarosis and blepharitis
Figure 5: Punctal agenesis

As highlighted above, patients with ED have several systemic manifestations, but of particular interest in this report are the ocular abnormalities. The previously reported ophthalmologic manifestations include strabismus, telecanthus, fused lids at birth, blepharophimosis, entropion, absence of eyelashes, bilateral eyelid cysts, agenesis of lacrimal puncta, dacryocystitis, blepharitis, conjunctivitis, deficient meibomian gland function, and corneal limbal deficiency. [8-12] There are few reports of the anhidrotic form among Nigerians. [24-26] However, to the authors' knowledge, this is the first case of the hidrotic form with ocular manifestations in Nigeria. ED is a disorder well documented in the dental and dermatological literature but in very few ophthalmological literature. The index child had the typical ocular associations, including complete agenesis of the upper and lower puncta bilaterally, madarosis and blepharitis, which have been documented in previous studies. [8-12]

The previous studies on ED with ocular association described bilateral involvement of the lacrimal apparatus, [27-28] also present in the index case. This informed our decision to do a conjunctivo-dacryocysto-rhinostomy (C-DCR) with a Lester Jones tube placement. The procedure was successful but post-operatively, the child developed a bilateral infection of the tubes, necessitating the removal of the tubes. Previous studies had attributed the tube infection to the stagnation of tears due to the poorly developed sino-nasal structures and chronic rhino-sinusitis, which are part of the disease spectrum. [28] However, the index child had no detectable disease manifestation on the ocular surface and posterior segment. Nevertheless, the child was closely followed up for early detection of other lately manifesting abnormalities in the eye, as documented by Marshall *et al.* [29]

This case report emphasizes the various pattern of systemic and ocular manifestations of the disease. Managing these patients, especially

those with significant systemic abnormalities can be challenging and requires a multi-disciplinary approach. The managing team should include the ophthalmologist, dental surgeon, plastic surgeon, dermatologist, surgeon, paediatrician and speech therapist. The family and caregivers must be very supportive as the disorder can lead to low self-esteem and reduced quality of life, considering the patient's obvious teeth, skin, hair and nail abnormalities.

Conclusion

Ectodermal dysplasia remains a rare condition seen in our environment. Management requires a multi-disciplinary approach. Therefore, it is essential to create awareness of this rare disease.

Authors' Contributions: OJFA conceived and designed the study along with MKF and YIB. All the authors participated in the literature review, drafting of the manuscript, and critical revision for sound intellectual content and approved the final version.

Conflicts of Interest: None.

Funding: Self-funded.

Publication History: Submitted 28 January 2023; Accepted 11 March 2023.

References

1. Thurnam J. Two cases in which the skin, hair and teeth were very imperfectly developed. *Proc RM Chir Soc* 1848;31:71-82.
2. Weech AA. Hereditary ectodermal dysplasia (congenital ectodermal defect). *Am J Dis Child* 1929; 37:766-790.
3. Kara NS. Ectodermal dysplasia. Updated 11 February 2019 <http://emedicine.medscape.com/article/1110595-overview> Accessed 02 January 2022.
4. Shafer, Hine, Levy. Diseases of the skin. In: Shafer's Textbook of Oral Pathology. 5th Ed. New Delhi: Elsevier publications; 2006. pp. 1099-102.
5. Pinheiro M, Freire-Maia N. The ectodermal dysplasias. *Arch Dermatol* 1982;118:215-216.
6. Pinheiro M, Freire-Maia N. Ectodermal dysplasias: A clinical classification and a causal review. *Am J Med Genet* 1994;53:153-162. <https://doi.org/10.1002/ajmg.1320530207>.
7. Khalekar Y, Zope A, Chaudhari L, Brahmanekar U. Ectodermal dysplasia. *Indian J. Multidiscip Dent.* 2016;6:55. <https://doi.org/10.4103/2229-6360.188239>.
8. Kaercher T. Ocular symptoms and signs in patients with ectodermal dysplasia syndromes. *Graefes Arch Clin Exp Ophthalmol* 2004;242:495-500. <https://doi.org/10.1007/s00417-004-0868-0>.
9. Mawhorter LG, Ruttum MS, Koenig SB. Keratopathy in a family with the ectrodactyly ectodermal dysplasia-clefting syndrome. *Ophthalmology* 1985;92:1427-1431.
10. Keklikci U, Yavuz I, Tunik S, Ulku ZB, Akdeniz S. Ophthalmic manifestations in patients with ectodermal dysplasia syndromes. *Adv Clin Exp Med* 2014;23:605-610. <https://doi.org/10.17219/acem/37235>.
11. Tyagi P, Tyagi V, Hashim AA. Ocular and non-ocular manifestations of hypohidrotic ectodermal dysplasia. *BMJ Case Rep* 2011;201. <https://doi.org/10.1136/bcr.01.2011.3731>.
12. Landau Prat D, Katowitz WR, Strong A, Katowitz JA. Ocular manifestations of ectodermal dysplasia. *Orphanet J Rare Dis* 2021;16:197 <https://doi.org/10.1186/s13023-021-01824-2>
13. Familusi J, Jaiyesimi F, Ojo C AE. Hereditary anhydrotic ectodermal

- dysplasia: Studies in a Nigerian Family. Arch Dis Child 1975;50:642-647.
14. Samaila MO, Ajike SO, Ogunrinde OG, Mohammed TT. Hypohidrotic Ectodermal Dysplasia in Black Africans. Eur J Gen Med 2013;10:167-169.
 15. Denloye OO, Dosunmu OO, Aderinokun GA, Onadeko MO. Ectodermal dysplasia with hypodontia in a set of Nigerian twins - a case report. Afr J Med Med Sci 1996;25:299-301.
 16. Ojo MA, Madukwe IU, Umweni AA, Mafeni JO. Hypohidrotic ectodermal dysplasia with total anodontia in a Nigerian child-A case report Nig. Dent J 1997;11:42-43.
 17. Olasoji O, Tahir A. Ectodermal dysplasia: A review and findings in two female siblings in a Nigerian Family. Online J Dent Oral Med 2003;5:1-9.
 18. Ogunrinde GO, Zubair RO, Aike SO, Ige SO. Hypohidrotic (anhidrotic) ectodermal dysplasia in female twins. Niger J Clin Pract 2012;15:98-100. <https://doi.org/10.4103/1119-3077.94109>.
 19. Lamartine J. Towards a new classification of ectodermal dysplasias. Clin. Exp. Dermatol. 2003;28:351-355. <https://doi.org/10.1046/j.1365-2230.2003.01319.x>.
 20. Priolo M, Lagana C: Ectodermal dysplasias: a new clinical-genetic classification. J Med Genet 2001;38: 579-585. <https://doi.org/10.1136/jmg.38.9.579>.
 21. Buyse M: Birth Defects Encyclopedia. Volume I. Ames, IA: Blackwell Scientific Publications, 1990.
 22. Achigbu K, Odinaka K, Amemilo I. Hypohidrotic Ectodermal Dysplasia: A Case Report in a Seven-Year-Old Nigerian Child. Niger Med Pract 2022;81:4-6.
 23. Ectodermal Dysplasia https://en.wikipedia.org/wiki/Ectodermal_dysplasia. Accessed 02 January 2022).
 24. Matsumoto Y, Dogru M, Goto E, Endo K, Tsubota K. Increased tear evaporation in a patient with ectrodactyly-ectodermal dysplasia-clefting syndrome. Jpn J Ophthalmol 2004;48:372-375. <https://doi.org/10.1007/s10384-003-0076-1>.
 25. Johnson A-W, Abdulkarim A, Adedoyin O, Adegboye A, Amole A. Anhidrotic ectodermal dysplasia: a case report in a Nigerian child and literature review. Niger J Paediatr 2012;39:79-83.
 26. Merz EH, Tausk K, Dukes E. Meso-ectodermal dysplasia and its variants, with particular reference to the Rothmund-Werner syndrome. Am J Ophthalmol 1963;55:488-504.
 27. Beckerman BL. Lacrimal anomalies in anhidrotic ectodermal dysplasia. Am J Ophthalmol 1973;75:728-730.
 28. Mondino BJ, Bath PE, Foos RY, Apt L, Rajacich GM. Absent Meibomian Glands in the Ectrodactyly, Ectodermal Dysplasia, Cleft Lip-Palate Syndrome. Am J Ophthalmol 1984;97:496-500.
 29. Marshall D. Ectodermal dysplasia; report of kindred with ocular abnormalities and hearing defect. Am J Ophthalmol. 1958;45:143-156. [https://doi.org/10.1016/0002-9394\(58\)90236-8](https://doi.org/10.1016/0002-9394(58)90236-8).



This is an Open Access document licensed for distribution under the terms and conditions of the Creative Commons Attribution License (<http://creativecommons.org/licenses/by-nc/4.0>). This permits unrestricted, non-commercial use, reproduction and distribution in any medium, provided the original source is adequately cited and credited.